



**EFP**

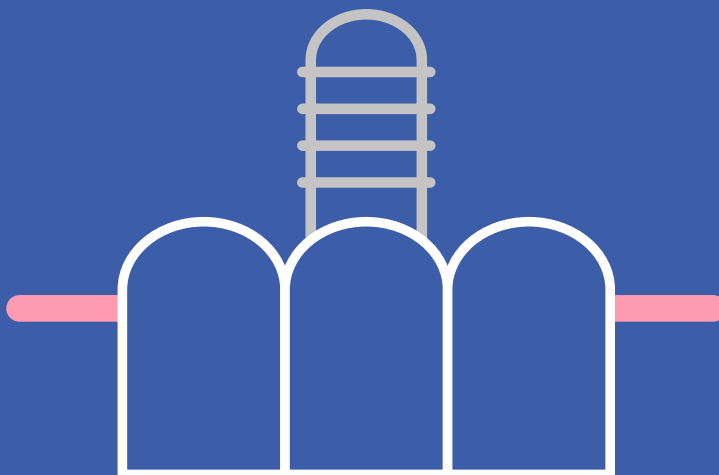
**New Classification**

of periodontal and peri-implant diseases

# 04. Peri-implant health, peri-implant mucositis, and peri-implantitis

## Guidance for clinicians

- The previous (1999) classification of periodontal diseases did not include peri-implant diseases and conditions.
- The 2017 World Workshop presented case definitions and considered the characteristics of peri-implant health, peri-implant mucositis, and peri-implantitis.
- Bleeding on probing (BoP) is used to distinguish between healthy and inflamed peri-implant mucosa.
- Bone loss is used to differentiate between peri-implant mucositis and peri-implantitis.
- The progression of peri-implantitis is faster than that observed in periodontitis and occurs in a non-linear and accelerating pattern.



Author Tord Berglundh

Published March 2019

© European Federation of Periodontology



---

# Peri-implant health, peri-implant mucositis, and peri-implantitis

---

## Introduction

Although a classification of peri-implant diseases and conditions was addressed for the first time in the 2017 World Workshop, definitions of peri-implant diseases had previously been presented at several editions of the EFP's European Workshop on Periodontology.

But the term “definition” has often provoked misunderstanding. There is a clear need to distinguish between a *disease* definition and a *case* definition. Disease definitions are descriptive and present the typical characteristics of the disease, whereas case definitions should provide the clinical guidelines for diagnosis (i.e. how to assess the condition).

At the 2017 World Workshop on Periodontology, Working Group 4 presented case definitions and addressed focussed questions on the characteristics of peri-implant health, peri-implant mucositis, and peri-implantitis.

The most important part of the case definitions is finding bleeding or suppuration on probing (BoP) and bone loss assessed in radiographs. BoP is the key tool to distinguish between healthy and inflamed peri-implant mucosa, while bone loss is used to differentiate between peri-implant mucositis and peri-implantitis. Bone loss in this context should exceed possible crestal-bone-level changes resulting from initial bone remodelling after implant placement.



---

**There is a clear need to distinguish between a disease definition and a case definition**

---

## Peri-implant health

---

Peri-implant hard and soft tissues are formed as a result of a wound-healing process following implant installation. The formation of new bone in contact with the implant is recognised as osseointegration, while the establishment of peri-implant mucosa includes the build-up of a junctional epithelium and a connective-tissue zone in contact with components of the implant.

Peri-implant health is characterised by the absence of clinical signs of inflammation, such as swelling, redness, and BoP. It is not possible, however, to define a range of probing depths that are compatible with health. In addition, peri-implant health can exist around implants with reduced bone support.

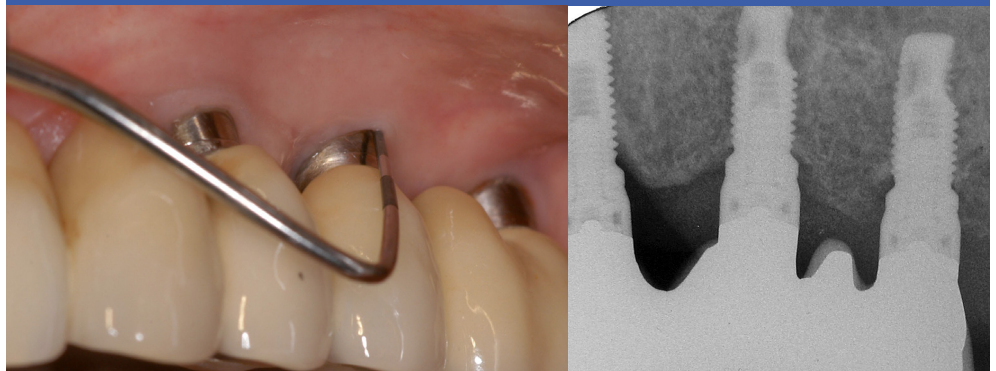
There are different scenarios in which peri-implant health may coincide with reduced bone support, as peri-implant health can be achieved at sites successfully treated for peri-implantitis. In addition, healing following implant placement in sites with ridge deficiencies may result in a bone level located apical of the implant margin and with parts of the peri-implant mucosa facing the intraosseous portion of the implant.

Case definition of peri-implant health in day-to-day clinical practice:

- absence of clinical signs of inflammation;
- absence of bleeding/suppuration on gentle probing;
- no increase in probing depth compared to previous examinations;
- no bone loss.

Image 1

Peri-implant health



---

**BoP is the key tool to distinguish between healthy and inflamed peri-implant mucosa, while bone loss is used to differentiate between peri-implant mucositis and peri-implantitis**

---

## Peri-implant mucositis

Peri-implant mucositis is characterised by an inflammatory lesion in the soft tissues surrounding an implant in the absence of loss of supporting bone. The lesion is located lateral to the junctional/pocket epithelium but does not extend into the supracrestal connective tissue zone “apical” of the junctional/pocket epithelium.

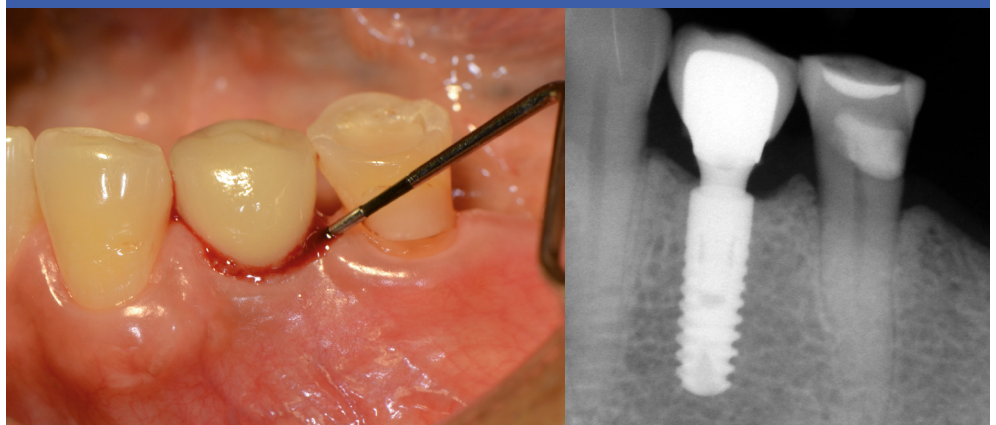
The main clinical characteristic of peri-implant mucositis is bleeding on gentle probing, while other clinical signs of inflammation – such as erythema and swelling – may also occur. An increase in probing depth is often observed in the presence of peri-implant mucositis because of swelling or a decrease in probing resistance. There is strong evidence that plaque is the aetiological factor involved in peri-implant mucositis. There is also evidence that peri-implant-mucositis lesions can resolve after the reinstatement of plaque-control procedures.

Case definition of peri-implant mucositis in day-to-day clinical practice:

- bleeding and/or suppuration on gentle probing;
- no bone loss.

Image 2

Peri-implant mucositis



---

**The progression of peri-implantitis is faster than that observed in periodontitis and occurs in a non-linear and accelerating pattern**

---

## Peri-implantitis

---

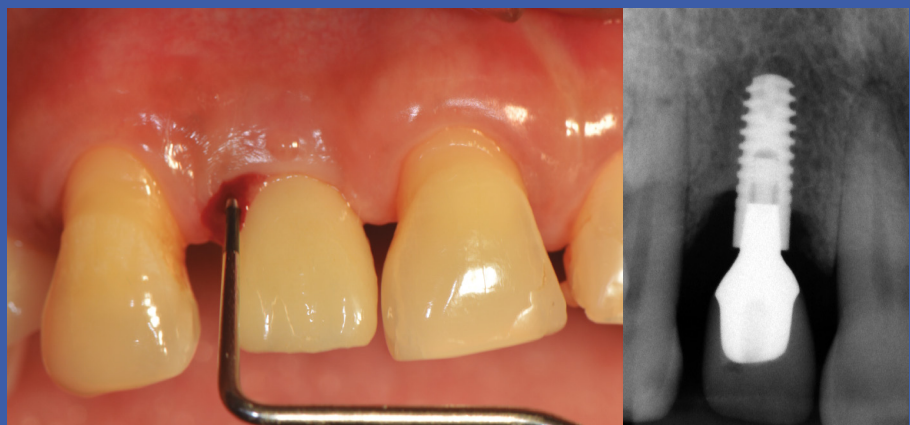Peri-implantitis is a plaque-associated pathological condition that occurs in tissues around dental implants. It is characterised by inflammation in the peri-implant mucosa and loss of supporting bone. Peri-implantitis sites exhibit clinical signs of inflammation including bleeding on probing and/or suppuration, increased probing depths and/or recession of the mucosal margin, and radiographic bone loss compared to previous examinations. Peri-implantitis lesions extend apical of the junctional/pocket epithelium and are larger than those at peri-implant mucositis and periodontitis sites.

Peri-implant mucositis is assumed to precede peri-implantitis. Data indicate that patients diagnosed with peri-implant mucositis may develop peri-implantitis, especially in the absence of regular maintenance care. The progression of peri-implantitis is faster than that observed in periodontitis and occurs in a non-linear and accelerating pattern.

The association between plaque and peri-implantitis is underpinned by evidence demonstrating that patients with poor plaque control who do not attend regular maintenance therapy are at higher risk of developing peri-implantitis and that anti-infective treatment strategies are successful in arresting disease progression. There is also strong evidence that there is an increased risk for peri-implantitis in patients who have a history of severe periodontitis. Data identifying smoking and diabetes as potential risk indicators for peri-implantitis are inconclusive.

Image 3

Peri-implantitis





**Case definition of peri-implantitis in day-to-day clinical practice:**

- bleeding and/or suppuration on gentle probing;
- increased probing depth compared to previous examinations;
- bone loss.

**Table 1. Case definitions in day-to-day clinical practice for peri-implant health, peri-implant mucositis, and peri-implantitis.**

Peri-implant health	Peri-implant mucositis	Peri-implantitis
No BoP	BoP	BoP
No bone loss*	No bone loss*	Bone loss*
*beyond crestal-bone-level changes resulting from initial bone remodelling		

**The case definition of peri-implantitis includes BoP and bone loss**

In the absence of previous examination data, a diagnosis of peri-implantitis can be based on the combination of:

- bleeding and/or suppuration on gentle probing;
- probing depths of  $\geq 6\text{mm}$ ;
- bone levels  $\geq 3\text{mm}$  apical of the most coronal portion of the intra-osseous part of the implant.



---

**Epidemiological studies should ideally include previous examinations performed after first year of implant loading**

---

## Case definitions in epidemiological studies

---

The same criteria used to define peri-implant health and peri-implant mucositis in day-to-day clinical practice should be applied in epidemiological studies. Similarly, the case definition of peri-implantitis in epidemiological studies is:

- bleeding and/or suppuration on gentle probing;
- increased probing depth compared to previous examinations;
- bone loss.

Epidemiological studies need to take into account the error of measurements in relation to assessments of bone-level changes. Bone loss should be reported using thresholds exceeding the measurement error (mean 0.5mm). Epidemiological studies should ideally include previous examinations performed after the first year of implant loading.

In the absence of previous radiographic examination data, bone levels  $\geq 3\text{mm}$  apical of the most coronal portion of the intra-osseous part of the implant, together with bleeding and/or suppuration on probing, are consistent with the diagnosis of peri-implantitis.

## Conclusion

---

The proposed case definitions should be viewed within the context of that there is no “generic” implant and that there are numerous implant designs with different surface characteristics and varying surgical and loading protocols. It is necessary to probe peri-implant tissues to assess changes in BoP and probing depth. It is recommended that clinicians obtain baseline radiographic and probing measurements following the completion of the implant-supported prosthesis.



### **Further reading**

[Proceedings of the World Workshop on the Classification of Periodontal and Peri-implant Diseases and Conditions](#), co-edited by Kenneth S. Kornman and Maurizio S. Tonetti. *Journal of Clinical Periodontology*, Volume 45, Issue S20, June 2018.

#### **Proceedings include:**

- Berglundh T, Armitage G, et al. [Peri-implant diseases and conditions: Consensus report of workgroup 4 of the 2017 World Workshop on the Classification of Periodontal and Peri-Implant Diseases and Conditions](#), pages S286-S291.
- Araujo MG, Lindhe J. [Peri-implant health](#), pages S230-S236
- Heitz-Mayfield LJA, Salvi G. [Peri-implant mucositis](#), pages S237-S245.
- Schwarz F, Derks J, Monje A, Wang H-L. [Peri-implantitis](#), pages S246-S266.
- Hämmerle CHF, Tarnow D. [The etiology of hard- and soft-tissue deficiencies at dental implants: A narrative review](#), pages S267-S277.
- Renvert S, Persson GR, Pirih FQ, Camargo PM. [Peri-implant health, peri-implant mucositis, and peri-implantitis: Case definitions and diagnostic considerations](#), pages S278-S285.


### **Author**



**Tord Berglundh**

**Tord Berglundh** is professor and chair at the Department of Periodontology at the Institute of Odontology, Sahlgrenska Academy at the University of Gothenburg, Sweden. He is co-editor of the textbook *Clinical Periodontology and Implant Dentistry* and associate editor of the journals *Clinical Oral Implants Research* and the EFP's *Journal of Clinical Periodontology*. He is a member of the editorial board of the *Journal of Dental Research* and serves as a referee on several other journals. He has received numerous scientific awards and produced about 230 scientific publications within the field of dental implants, periodontal and peri-implant diseases, immunology, genetics, tissue integration, and regeneration.





## **New Classification of periodontal and peri-implant diseases and conditions**

The New Classification is the product of the World Workshop on the Classification of Periodontal and Peri-implant Diseases and Conditions, held in Chicago in November 2017. The World Workshop was organised jointly by the American Academy of Periodontology (AAP) and the European Federation of Periodontology (EFP) to create a consensus knowledge base for a new classification to be promoted globally. The New Classification updates the previous classification made in 1999. The research papers and consensus reports of the World Workshop were published simultaneously in June 2018 in the EFP's *Journal of Clinical Periodontology* and the AAP's *Journal of Periodontology*. The new classification was presented formally by the two organisations at the EuroPerio9 congress in Amsterdam in June 2018.



### **About the EFP**

The European Federation of Periodontology (EFP) is an umbrella organisation of 35 national scientific societies devoted to promoting research, education, and awareness of periodontal science and practice. It represents more than 14,000 periodontists and gum-health professionals in Europe alone. In addition to 31 European members, the EFP has recently welcomed four international associate members from Asia, the Middle East, and Latin America.

---

[www.efp.org](http://www.efp.org)  
[www.efp.org/newclassification](http://www.efp.org/newclassification)

European Federation of Periodontology  
Avenida Doctor Arce, 14. Office 38  
28002 Madrid  
Spain