

Rapporteurs:

Liron Kabakov, Yehonathan Friedlander, Daniel Rotenberg, Amin Younis, and Benjamin Coyac, with Jacob Horwitz

Affiliation:

EFP-accredited programme in periodontology at Rambam Health Care Campus, Israel

study

To seal or not to seal? What is the deal in ridge preservation?

Authors:

João Roig Martins, Tassiane Panta Wagner, Ana Carolina Vallim, Willian Konflanz, Falk Schwendicke, Roger Keller Celeste, Alex Nogueira Haas

Background

Tooth extraction results in atrophy of the alveolar bone, which may impact the placement of an implant. Several bone-regenerative techniques are employed to counteract these anatomic alterations.

These procedures can involve various socket-seal approaches – such as primary closure with a coronally advanced flap or by means of a barrier with open healing, or open healing and no barrier.

While the efficacy of alveolar-ridge preservation has been widely investigated in various systematic reviews and meta-analyses, there is a lack of information regarding the comparison of specific socket-seal techniques.

Aim

To find out which socket-seal technique has the best potential to contribute to alveolar-ridge preservation.

Materials & methods

- The authors systematically reviewed clinical trials assessing different socket-seal techniques:
 - Alveolar-ridge preservation with “primary closure”:
 - coronally advanced flap;
 - free gingival graft;
 - connective tissue graft.
 - Alveolar-ridge preservation without primary closure (exposed barrier), and techniques with no socket seal:
 - alveolar-ridge preservation (no barrier)
 - no ridge preservation (spontaneous healing)
- All alveolar-ridge comparisons were made at least two months after tooth extraction, and on the horizontal dimension, either by clinical measurement or radiographic evaluation.
- The authors then performed a statistical analysis to rank the techniques according to their clinical efficacy.

Figure: Network map for clinical and tomographic outcomes after alveolar-ridge preservation with three sealing approaches or spontaneous healing.

The size of the nodes is proportional to the number of patients receiving each treatment, whereas the width of the lines is proportional to the number of trials proportional comparing the connected treatments

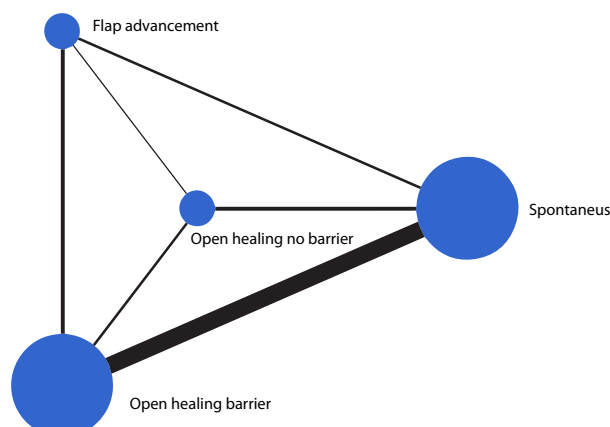


Table: Comparative effect sizes (mean ridge-width change in millimetres) and probability of being the best treatment (ranks) for each sealing approach and estimated from network meta-analysis

Reference treatment	Comparative treatment	Effect size *	95% predictive interval
Spontaneous healing	Primary closure	1.18	0.21 to 2.13
	Open healing with barrier	1.10	0.49 to 1.69
	Open healing without barrier	0.46	- 0.70 to 1.64
Primary closure	Open healing with barrier	- 0.08	- 1.02 to 1.64
	Open healing without barrier	- 0.71	- 1.98 to 0.57
Open healing with barrier	Open healing without barrier	- 0.62	- 1.78 to 0.54
Probability of being the best treatment			
	Primary closure	52.7	
	Open healing with barrier	39.1	
	Open healing without barrier	8.2	
	Spontaneous healing	0.0%	

Reference treatment Comparative treatment Effect size α 95% Predictive interval * Positive values indicate higher ridge width in the comparative treatment than in the reference treatment. Negative values indicate lower ridge width in the comparative treatment than in the reference treatment.

Results

- Twenty-two clinical trials were included in the study.
- While the sole grafting of a bone substitute in the extraction socket was equivalent to doing nothing in terms of alveolar-ridge horizontal shrinkage after two months, adding a barrier membrane was beneficial.
- When, instead of a membrane, the socket was covered by a coronally-advanced flap, a free gingival graft, or a connective-tissue graft, the width of the ridge was more efficiently preserved.
- No significant differences existed between alveolar-ridge preservation with primary closure of the socket and alveolar-ridge preservation with secondary healing (with or without a barrier).
- In addition, no significant differences were found between the different socket-seal techniques.

Limitations

- Only the horizontal bone dimension was evaluated in this systematic review, which excluded the vertical dimension. A full evaluation cannot be made without this critical information.
- In addition, as in most meta-analyses in the field of dentistry, the heterogeneity (variation in outcomes between studies) is very high. This means that any conclusion drawn from the results of statistical comparison should be taken with reservation.

Conclusions & impact

- To maintain the width of the ridge, using only a bone-graft substitute within an extraction socket provides little or no benefit.
- The socket needs to be sealed: the graft needs to be covered in order to reduce changes in the width of the alveolar bone.
- The best way to cover the bone-graft substitute is with autogenous tissue, such as a coronally advanced flap, a free gingival graft, or a connective-tissue graft.
- This article provides evidence-based support for covering a bone-graft substitute to reduce horizontal post-extraction shrinkage of the alveolar ridge.

 JCP Digest 103 is a summary of 'Comparison of the efficacy of different techniques to seal the alveolus during alveolar ridge preservation: Meta-regression and network meta-analysis' J Clin Periodontol. 49(7):694-705. DOI: 10.1111/jcpe.13628

 <https://www.onlinelibrary.wiley.com/doi/10.1111/jcpe.13628>

 Access through EFP members' page log-in: <http://efp.org/members/jcp.php>