

Summarised from *Journal of Clinical Periodontology* Volume 47, issue 4 (April 2020), 470-478

Editors: Phoebus Madianos & Andreas Stavropoulos, EFP scientific affairs committee

**Rapporteurs:**

Panagiota Vagia, Sonia Deschamps-Lenhardt, Guilhem Jolivet, Maria Vilar Doceda, and Pierre-Yves Gegout with Prof Henri Tenenbaum and Prof Olivier Huck

**Affiliation:**

Postgraduate programme in periodontology and implant dentistry, University of Strasbourg, France

*study*

# Entire-papilla preservation is an effective technique to treat intrabony defects

**Authors:**

Serhat Aslan, Nurcan Buduneli, Pierpaolo Cortellini

## Background

Periodontal tissue regeneration is the ultimate goal of periodontal therapy. Various surgical and non-surgical procedures and different biomaterials have been described and tested and have shown positive outcomes. However, several factors may affect the clinical outcomes, including the presence of plaque, tissue inflammation, defect anatomy, and smoking habits. The most frequent complications, which worsen the treatment outcome, are the exposure of the biomaterials and the loss of the gingival papilla. These complications are associated with surgical techniques that require a papillary incision.

To avoid such complications, alternative approaches have been proposed, such as the use of enamel matrix derivatives (EMD), alternative flap designs (papilla-preservation techniques), and minimally invasive techniques.

A novel approach – entire-papilla preservation (EPP) – has been proposed, which is intended to treat isolated deep intrabony defects while keeping an intact gingival chamber over the defect and therefore completely preserving interdental papillae. The efficiency of the EPP technique has already been proven by a one-year prospective cohort study.

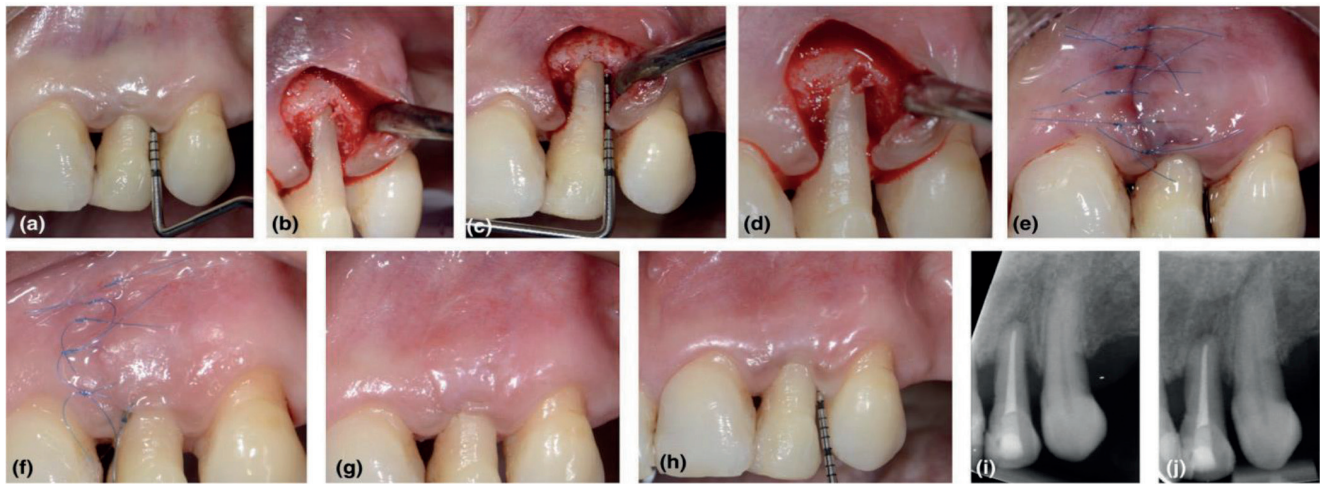
## Aims

The main objective of this randomised clinical trial was to compare the clinical efficacy of EPP alone versus EPP combined with both EMD and bovine-derived bone substitute (BDS).

## Materials & methods

- This study was a parallel group, randomised, controlled clinical trial including 15 patients per group.
- Inclusion criteria:
  - One isolated intrabony defect with probing depth (PD)  $\geq 7$ mm, clinical attachment level (CAL)  $\geq 8$ mm, and an intrabony component  $\geq 4$ mm measured on digital periapical radiographs involving the interproximal area.
  - Full-mouth plaque score (FMPS) and full-mouth bleeding score (FMBS)  $\leq 20\%$ .
- Exclusion criteria:
  - Current smokers, systemic diseases, medications affecting periodontal tissues, and pregnant or breastfeeding women.
  - One-wall intrabony defects and defects involving the buccal and the lingual side of the tooth.
  - Inadequate endodontic treatment and/or restoration.
- The clinical parameters measured immediately before regenerative surgery and after 12 months of follow-up were: FMPS, FMBS, PD, recession of the gingival margin (REC), and CAL (calculated as the sum of PD and REC).
- A buccal intra-crevicular incision and a vertical incision contralateral to the osseous defect were performed, followed by an interdental tunnel preparation. In the test group (EPP + EMD + BDS), EMD and BDS were placed into the intrabony defect, whereas in the control (EPP) group, the intrabony defect was filled with only a blood clot (see figure).
- Patients followed oral-hygiene reinforcement on a weekly basis for the first month and then monthly controls for professional tooth-cleaning for up to one year.

Figure: Surgical procedure



Representative case treated with the entire papilla preservation technique (EPP group) without regenerative materials. (a) A 10mm preoperative probing depth at the distal side of the maxillary left lateral incisor. (b) Interdenal tunnel preparation by undermining the defect-associated papilla. Note the elasticity of alveolar mucosa and full access to the defect area helped by a single vertical incision. (c) Defect measurement with UNC-15 periodontal probe. (d) After the application of 24% EDTA gel, bleeding from residual bone walls. (e) Primary closure of surgical area following the blood-clot formation using microsurgical knots and intact interdenal papilla. (f) Fourteen days after the surgery. (g) Excellent wound healing and integrity of defect-associated interdenal papilla. (h) The one-year photograph shows 3mm of residual probing depth and a CAL gain of 7mm. There was no occurrence of gingival recession. (i) Baseline radiograph. (j) One-year radiograph.

## Results

- Both groups were homogeneous and no significant differences were observed in terms of age, gender (Test =  $44.93 \pm 13.06$  years, five females; Control =  $43.93 \pm 12.85$  years, seven females), tooth type, severity, and morphology of the intrabony defect (X-ray angle: Test =  $28.8^\circ \pm 8.76^\circ$ ; Control =  $29.33^\circ \pm 9.48^\circ$ ).
- The experimental sites were mainly two-wall intrabony defects (13/15 for the EPP + EMD + BS group; 14/15 for the EPP group); the remaining sites were three-wall defects.
- Primary wound closure was obtained in all treated sites and the early healing phase was uneventful in all cases.
- Surgical time for EPP alone was shorter (55.07 min on average,  $\pm 39$ -68 min) than for EPP + EMD + BS (65.4 min on average,  $\pm 50$ -93 min).
- Only one patient in each group reported slight post-operative discomfort.
- Clinical outcomes at one year. No significant differences were observed:
  - Gingival recession ( $2.53\text{mm} \pm 1.36\text{mm}$  vs  $2.5\text{mm} \pm 1.4\text{mm}$ ).
  - CAL gain ( $6.3\text{mm} \pm 2.5\text{mm}$  vs  $5.83\text{mm} \pm 1.12\text{mm}$ ).
  - PD reduction ( $6.5\text{mm} \pm 2.65\text{mm}$  vs  $6.2\text{mm} \pm 1.33\text{mm}$ ).
  - Increase in gingival recession ( $0.2\text{mm} \pm 0.25\text{mm}$  vs  $0.36\text{mm} \pm 0.54\text{mm}$ ).

## Limitations

- Lack of aesthetic evaluation of the outcome of the surgical procedure.
- Bone sounding before surgery and periapical radiographs may not be as accurate as 3D radiographic examinations to assess defect anatomy (number of walls).
- A longer follow-up is needed to validate the stability of the results.
- Further RCTs comparing different surgical techniques are needed to assess the benefit of one papilla-preservation technique over the other.

## Conclusions & impact

- Within the limitations of this study, it can be concluded that the EPP surgical technique without adjunctive use of biomaterials is effective in terms of CAL gain.
- This technique is ideal to apply in isolated two-wall interproximal intrabony defects with a missing buccal bony wall.
- Because of the lack of elevation of the interdenal papilla, first-intention healing is achieved.
- Patients were satisfied by the surgical procedure and experienced no complications.

JCP Digest 76, published in July 2020, is a summary of the article 'Clinical outcomes of the entire papilla preservation technique with and without biomaterials in the treatment of isolated intra-bony defects: A randomized controlled clinical trial.' J Clin Periodontol. 2020; 47 (4), 470-478. DOI: 10.1111/jcpe.13255

<https://www.onlinelibrary.wiley.com/doi/epdf/10.1111/jcpe.13255>

Access through EFP members' page log-in: <http://efp.org/members/jcp.php>