

Summarised from *Journal of Clinical Periodontology*, Volume 49, issue 4 (April 2022), 401-411

Editor: Andreas Stavropoulos, chair, EFP scientific affairs committee

Rapporteurs:

Chin Hoi Man Bonnie, Kwok Chee Yin, Lam Pok Man, and Tsang Nichol Chun Wai, with George Pelekos

Affiliation:

EFP-affiliated programme in periodontology at the University of Hong Kong

study

Implant placement with soft-tissue grafting: when and how?

Authors:

Kwang-Seok Lee, Seung-Yun Shin, Christoph H. F. Hämmerle, Ui-Won Jung, Hyun-Chang Lim, and Daniel S. Thoma

Background

Soft-tissue grafting procedures are often performed to improve aesthetic outcomes and to compensate for existing volume deficiencies. Clinical data have demonstrated that soft-tissue surgery contributes to more than 40% of the final horizontal or buccal volume. The "gold-standard" procedure for soft-tissue volume augmentation is the use of a subepithelial connective-tissue graft (CTG). However, harvesting procedures cause increased patient morbidity because of the presence of a donor site.

Soft-tissue substitutes were developed to overcome these issues. In pre-clinical canine studies, soft-tissue substitutes and CTG demonstrated a similar effect on soft-tissue volume increase at implant sites. A recent clinical study (Thoma et al., 2016) indicated the non-inferiority of soft-tissue substitutes for implant sites compared with CTG. However, previous data regarding soft-tissue substitutes are limited to specific implant treatment protocols and, more specifically, to delayed placement.

Considering that various treatment protocols exist – such as immediate implant placement (IP), early implant placement (EP), and implant placement following alveolar ridge preservation (ARP) – the effectiveness of soft-tissue substitutes for soft-tissue volume augmentation using different implant placement protocols needs to be further evaluated and compared with CTG.

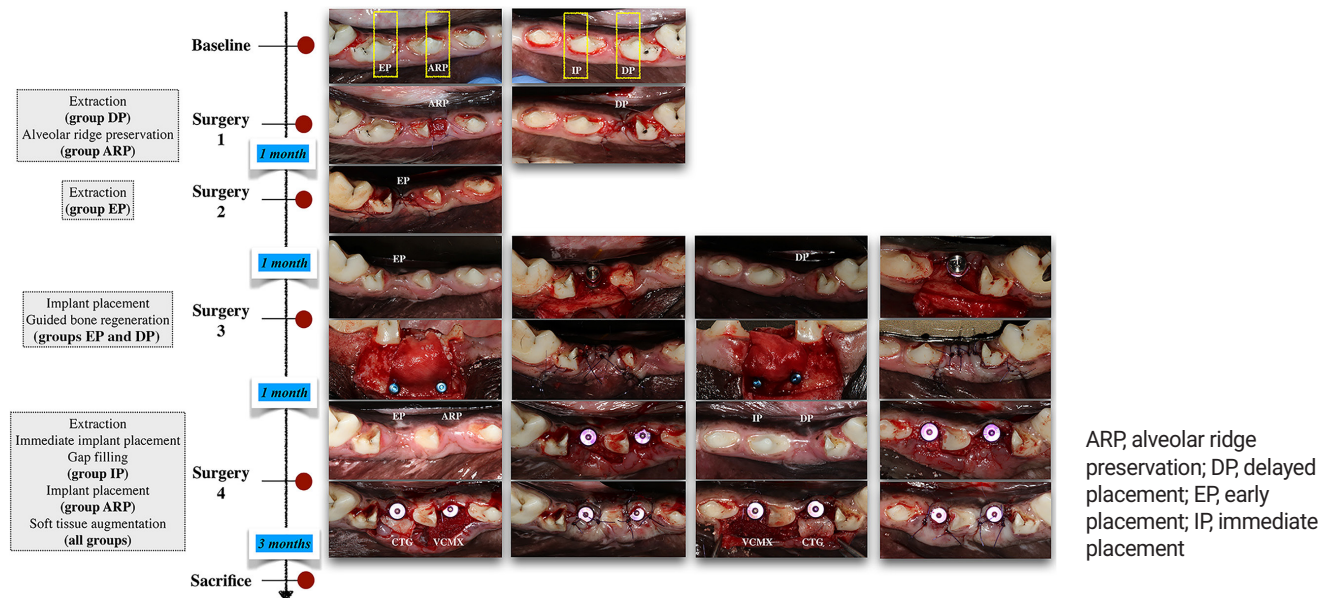
Aim

The aim of this study is to determine the effect of the timing of implant placement and the type of soft-tissue graft in terms of changes to the ridge profile.

Materials & methods

- The third mandibular and fourth premolars were hemisected and the mesial roots extracted. The implants were 4 x 10 or 12mm, Luna, Shinhung, Seoul, Korea, and the healing abutments were 4 x 4mm.
- ARP was performed with deproteinised bovine bone material (DPBM) with 10% collagen (Bio-Oss collagen, Geistlich, Wolhusen, Switzerland) and a collagen matrix (Mucograft seal, Geistlich), and implant installation was performed after three months of healing.
- IP was combined with deproteinised bovine bone mineral (Bio-Oss, Geistlich) filling the gap between the implant and the buccal bone plate.
- Implant installation at the EP and DP groups was performed one and two months after extraction respectively, and included guided bone regeneration (GBR) using deproteinised bovine bone mineral (Bio-Oss, Geistlich) and a native bilayer collagen membrane (BioGide, Geistlich) at the buccal aspect of the implant. EP and DP implants were exposed after one month of healing.
- In all groups, a partial-thickness flap was raised at the buccal side of the implants for either a CTG or VCMX (Fibrogide, Geistlich).
- All the animals were sacrificed months after soft-tissue surgery. Microcomputed tomography scanning and intraoral scanning were performed at different time points. Linear measurements were performed to observe the ridge-contour changes between different timepoints. The overall change of ridge width throughout the study, the change resulting from bone augmentation, and the change caused by soft-tissue augmentation were measured.
- Profilometric measurement was obtained at a region 2mm apical to the gingival margin and extended 2mm apically with a 4mm width. Changes across timepoints were observed.

Figure: Flow-chart and clinical photographs of the surgeries.



Results

- No adverse event was observed.
- Micro-CT scans revealed bone remodelling around implants, and bone dehiscences were observed on the buccal surface. The IP group showed the most favourable result.
- Linear measurement:
 - Overall change
 - 2mm level – all except ARP/CTG (0.07mm) demonstrated horizontal shrinkage, ranging from -0.09mm in DP/VCMX to -1.87mm in EP/CTG.
 - 3mm level – similar ridge width was found in DP/CTG (0mm) and ARP/CTG (0.03mm), otherwise there was shrinkage, ranging from -0.13mm in EP/VCMX to -1.59mm in EP/CTG.
 - Hard tissue
 - 2mm level – gain in EP (0.87mm) and DP (0.93mm).
 - 3mm level – gain in EP (0.95mm) and DP (0.92mm).
 - Soft tissue
 - 2mm level – all except EP/VCMX (-0.20mm) demonstrated gain, ranging from 0.13mm in EP/CTG to 1.25mm in DP/CTG.
 - 3mm level – gain in all groups, ranging from 0.16mm in EP/VCMX to 0.97mm in EP/CTG.
- Profilometric measurement:
 - Overall change
 - Gains found in ARP/CTG (0.17mm) and DP/CTG (0.05mm), but losses were observed elsewhere, ranging from -0.02mm in ARP/VCMX to -1.19mm in EP/CTG.
 - Hard tissue
 - Larger median increase in DP (0.82mm) compared to EP (0.52mm).
 - Soft tissue
 - Gain in all groups, ranging from 0.14mm in DP/VCMX to 0.79mm in DP/CTG.
- No statistically significant differences within each group (overall, hard tissue, and soft tissue).

Limitations

- The study may not be able to reflect the whole picture regarding soft-tissue remodelling after the procedures because animals were used and large clinical trials are necessary.
- There were no detailed discussions on the materials and methods used for the volumetric analysis in this study.

Conclusions & impact

- Within the limitations of this study, ARP and DP with CTG led to the smallest tissue change between pre-extraction and the study's final time point, compared to other treatment modalities (without statistically significant difference).
- CTG and VCMX enhanced the overall tissue contour at the implant sites, when applied to EP or DP and ARP.
- Even though soft-tissue augmentation and gap filling were performed, IP sites had reduced tissue contours.
- Dimensional ridge changes varied between treatment protocols. ARP with CTG led to the smallest difference in ridge profile. Both CTG and VCMX were able to enhance the ridge contour.
- Based on the results of this pilot pre-clinical study, large clinical trials are required to determine the most favourable timing for implant placement and the preferred soft-tissue grafting modality for achieving optimal tissue profile.

JCP Digest 100, published in May 2022, is a summary of 'Dimensional ridge changes in conjunction with four implant timing protocols and two types of soft tissue grafts: A pilot pre-clinical study.' *J Clin Periodontol.* 49(4):401-411. DOI: 10.1111/jcpe.13594

<https://www.onlinelibrary.wiley.com/doi/10.1111/jcpe.13594>

Access through EFP members' page log-in: <http://efp.org/members/jcp.php>