

Summarised from *Journal of Clinical Periodontology*, Volume 50, issue 4 (April 2023), 500-510

Editor: Andreas Stavropoulos, chair, EFP scientific affairs committee

Rapporteurs:

Alessandra Bandel and Walter Castelluzzo, with Luigi Barbato and Prof. Francesco Cairo

Affiliation:

Postgraduate programme in periodontology, University of Florence, Italy

study

Alveolar phenotype may represent the limit of horizontal GBR

Authors:

Marc Quirynen, Pierre Lahoud, Wim Teughels, Simone Cortellini, Rutger Dhondt, Reinhilde Jacobs, Andy Temmerman

Background

When planning implant therapy, a common problem is that the alveolar ridge lacks adequate dimensions. Guided bone regeneration (GBR) is an effective procedure to provide sufficient volume to allow prosthetically driven surgery, but the buccal graft may be exposed to resorption over time.

Most resorption takes place during the early phases of integration and regeneration (early resorption), but it can continue in the long term (late resorption). Various determinants may affect the stability of lateral GBR, ranging from defect morphology to the selected technique and the type of applied biomaterial.

There is only limited information on the possible impact of the natural alveolar crest contour or "individual phenotypic dimension" (IPD) on GBR outcomes. IPD may be represented by the bony dimensions of the contralateral healthy site – measured on cone beam computed tomography (CBCT) – and this could represent the anatomical limit of alveolar bone augmentation and therefore determine the degree of resorption of the graft independently of the extent of horizontal overcontouring.

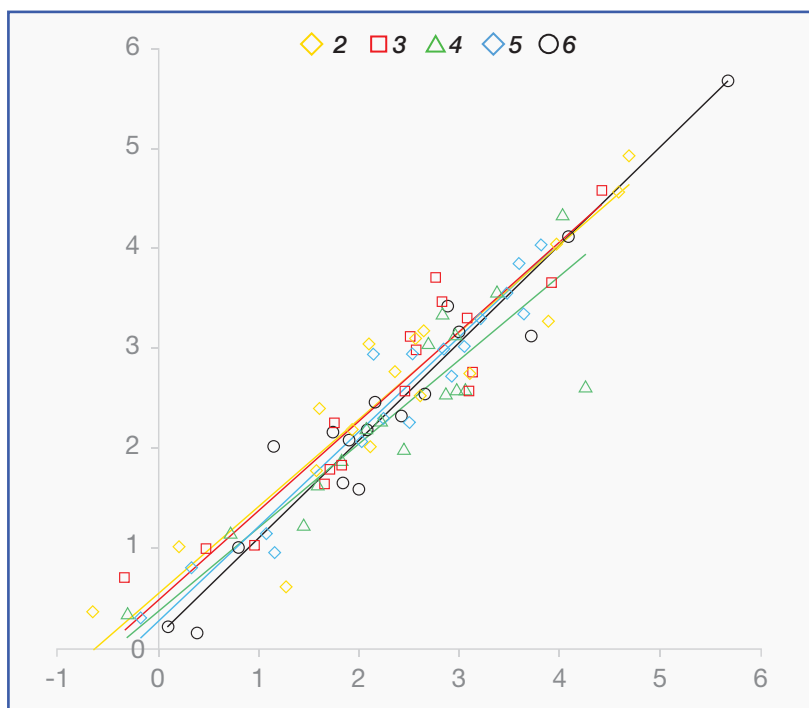
Aim

This study sought to evaluate whether the volume of the contralateral healthy site (IPD), measured by CBCT, can predict the degree of resorption after a GBR procedure in terms of linear and volumetric dimensions.

Materials & methods

- A retrospective cohort study that analysed a database of patients who had received a maxillary guided bone regeneration (GBR) procedure.
- Patients were included in the study if they presented:
 - A relatively symmetrical maxillary arch.
 - Intact contralateral alveolar bone dimension.
 - Pre-operative CBCT.
 - CBCT taken immediately after GBR.
 - At least one CBCT taken six to eight months after surgery (to evaluate early resorption) and/or ≥ 12 months after implant placement to measure the impact of early resorption and late resorption.
- Using 3D virtual reconstruction and superimposition of CBCT, the volumetric stability of lateral augmentation was evaluated at different timepoints.
- The bony contour of the contralateral healthy site – representing the IPD of the alveolar crest – was superimposed on the GBR site using Mimics software (Materialise, Leuven, Belgium).
- Linear measurements were made, beginning 2mm apical to the most coronal part of the graft up to 10mm apically.
- A volumetric analysis of the entire GBR, was made 2mm away from the mesial, distal, and apical border for standardisation.
- Statistical analysis was performed using a linear mixed model and a regression analysis for 2D measurements together with a part-comparison analysis (SPCA) for volumetric assessment.

Figure: Correlation between the amount of initial bone augmentation beyond the mirrored line and the amount of graft resorption ≥ 1.5 years after GBR (early resorption and late resorption together)



Note: Measurements were performed at different levels (2mm, 3mm, 4mm, 5mm, and 6mm apical to the alveolar crest)

Results

- Twenty-three GBR sites from 17 patients were analysed and divided in three groups depending on the available CBCT data, to evaluate the impact of (I) early resorption, (II) early resorption and late resorption together, and (III) early resorption and late resorption separately.
- Different types of edentulous sites were treated. A collagen membrane was used as a barrier in all cases, but different regenerative materials were employed.
- Immediately after the surgical procedure, the mean amount of bone augmentation, measured 2mm from the most coronal part of the graft, was 5.0 ± 2.1 mm.
- After six to eight months of healing, the amount of bone regeneration was reduced to 3.7 ± 2.2 mm. This means that the graft was overlapping the mirrored IPD by about 0.7mm.
- At a late healing stage (≥ 18 months), bone augmentation was further reduced to about 2.5mm and the outline of the graft almost perfectly matched the mirrored IPD.
- Both 2D and 3D analysis showed a very high correlation between the final amount of bone regeneration and the IPD (mean deviation $0.0\text{mm} \pm 0.5\text{mm}$). Also, the amount of bone “outside” the IPD immediately after the surgical procedure correlated very well with the final amount of graft resorption after 1.5 years (correlation coefficients ranged from 0.84 to 0.98; $p < 0.001$).

Limitations

- The number of patients available for the analysis was very limited.
- No information was given on the anatomy of the treated defects or the reason for tooth loss. Different anatomical configurations of the defect may influence the outcomes of the regenerative procedure.
- Different materials were applied for horizontal guided bone-regeneration procedures. Sub-analysis conducted by the authors showed no differences between L-PRF bone block and composite bone block (50% Bio-Oss + 50% autogenous bone) – but this was observed in a very limited subsample of patients, thus hindering the ability to make generalisations from the outcomes.

Conclusions & impact

- It is noticeable that, following a GBR procedure, a significant portion of the graft undergoes resorption. Both early and late resorption were around 1mm.
- The individual bone phenotype seems to be a good predictor of the resorption process. After 18 months of healing, the outline of the grafts fits almost perfectly with the IPD, as measured by CBCT.
- This finding could guide clinicians in determining the maximum amount of bone that can be regenerated through GBR, although further research with a larger sample of patients is necessary.

JCP Digest 112, published in April 2023, is a summary of 'Individual “alveolar phenotype” limits dimensions of lateral bone augmentation' *J Clin Periodontol.* 2023; 50(4):500-510. DOI: 10.1111/jcpe.13764

<https://www.onlinelibrary.wiley.com/doi/10.1111/jcpe.13764>

Access through EFP members' page log-in: <http://efp.org/members/jcp.php>