

Scientific release
from the European
Federation of
Periodontology

Rapporteurs: Eshkol-Yogev Inbar,
Asher Ran, Grossman Arnon,
Horwitz-Berkun Rachel with
Goldstein Moshe.

For the Original Article please go to:
<http://www.efp.org/members/jcp.php>
Login and navigate to Volume 41, Issue 1

Affiliation: Prepared by the residents
from the Postgraduate Program of
Periodontology at the Dept of
Periodontology, Faculty of Dental
Medicine, the Hadassah-Hebrew
University Medical Center, Jerusalem,
Israel.

Study:

Extraction Sockets: Erratic Healing Impeding Factors

Kim JH, Susin C, Min JH, Suh HY, Sang EJ, Ku Y, Wikesjo UM, Koo KT. *J Clin Periodontol. Jan 2014; 41; 80-85.*

Summarised from original article with kind permission from Wiley Online Library
Copyright © 1999-2014 John Wiley & Sons, Inc. All Rights Reserved.

Relevant background to study:

In day-to-day clinical practice, adverse reactions following tooth extraction may arise and can result in impaired healing, which may reduce resulting socket bone fill and compromise definitive space restoration by implant placement.

“Erratic healing” in the reported study is defined as extraction sockets that became occupied by soft tissue infiltration and required repeated debridement followed by guided bone regeneration at the time of implant placement.

Study Aims:

The aim of this study was to analyze the prevalence of extraction sockets with fibrous scar tissue occupying the extraction site (rather than bone)

following 12 or more weeks of healing and to evaluate the associated risk factors.

Methods:

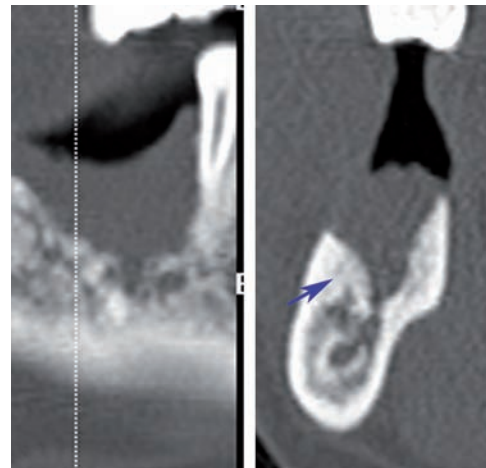
Computerized tomography was used to evaluate socket characteristics and calculate “Hounsfield unit” scores (an index used to assess bone mineral density)

A total of 1226 dental records from Seoul National University Dental Hospital archives including patients subjected to extractions prior to implant placement were evaluated.

Results:

Seventy subjects (5.71%) and 97 sites (4.24%) exhibited impaired extraction socket healing. Maxillary incisor/canine sites showed the lowest prevalence (0.47%), whereas mandibular molar sites the highest (5.41%) occurrence.

72% of the cases of erratic healing were of teeth extracted due to periodontal reasons.



CT scan of a site with erratic healing, 12 months after molar tooth extraction

Conclusions and impact:

Conclusions: The factors that were associated with erratic healing were:

- Age- subjects older than 60 years
- Hypertension
- Teeth- molars showed more erratic healing
- Site- the highest incidence of bone loss was at the buccal wall (49.3%)
- Single tooth extractions
- The vast majority of erratic healing sites (72%) where of teeth extracted for periodontal reasons.

Impact: What can we learn as practitioners?

- Erratic extraction socket healing appears not to be a uncommon phenomenon! It may arise in one in every twenty cases!
- Spontaneous socket healing (without socket preservation) resulted in good healing in the vast majority of cases.
- When planning tooth extractions one should be aware of systemic and local factors that may be major contributors to erratic healing - older patients, hypertensive patients, cases of mandibular molars and advanced periodontal disease.